


EP CASE REPORT

Transient complete left bundle branch block during left fascicular ventricular tachycardia

Bin-Feng Mo , Jian Sun, Peng-Pai Zhang, Qun-Shan Wang *, and Yi-Gang Li

Department of Cardiology, Xinhua Hospital, Shanghai Jiaotong University, School of Medicine, #1665 Kong Jiang Road, Shanghai 200092, China

* Corresponding author. Tel: +86 (21) 2507 7260; fax: +86 (21) 2507 7225. E-mail address: wangqunshan@xinhumed.com.cn

A 21-year-old man who had successful ablation of left posterior fascicular (LPF) ventricular tachycardia (VT) at the middle septum of the left ventricle 8 years ago was referred to our institution due to recurrent palpitation. The 12-lead electrocardiogram (ECG) during sinus rhythm (Figure 1A) demonstrated an S-wave in leads I and aVL, a small Q-wave and tall R-wave in the inferior leads and a slightly wide QRS complex (108 ms) as a result of previous ablation at the LPF vicinity. During tachycardia, the ECG demonstrated a wider QRS complex (120 ms) and right axis with a cycle length of 330 ms, rSr' pattern in lead V1, and VA dissociation. The H-V interval during sinus rhythm was 48 ms and it shortened to 21 ms during the tachycardia (Figure 1B), which suggested a left upper septal exit. When mapping at the left anterior fascicle (LAF) area using the ablation catheter during tachycardia (Figure 1D, blue dot), a typical complete left bundle branch block (CLBBB) occurred (Figure 1C), which may be caused by mechanically traumatizing the LAF. However, VT was not terminated or prolonged. VT with a typical CLBBB morphology maintained for 16 s and then changed back to the former morphology VT (Figure 1C). This fascicular VT was successfully ablated by targeting the earliest Purkinje potential during tachycardia near the proximal area of LPF (Figure 1D).

Nearly half of left upper septal fascicular VTs occurred after ablation targeting LPF VT and the mechanism of this VT was still controversial.^{1,2} Typical CLBBB during tachycardia in this case suggested a mechanism of a small circuit near the left upper septal.

Conflict of interest: none declared.

References

1. Talib AK, Nogami A, Nishiuchi S, Kowase S, Kurosaki K, Matsui Y et al. Tachycardia: prevalence, mechanism, and electrophysiological characteristics. *JACC Clin Electrophysiol* 2015;**1**:369–80.
2. Guo XG, Liu X, Zhou GB, Sun Q, Yang JD, Luo B et al. Clinical, electrocardiographic, and electrophysiological characteristics of left upper septal fascicular ventricular tachycardia. *Eurpace* 2018;**20**:673–81.

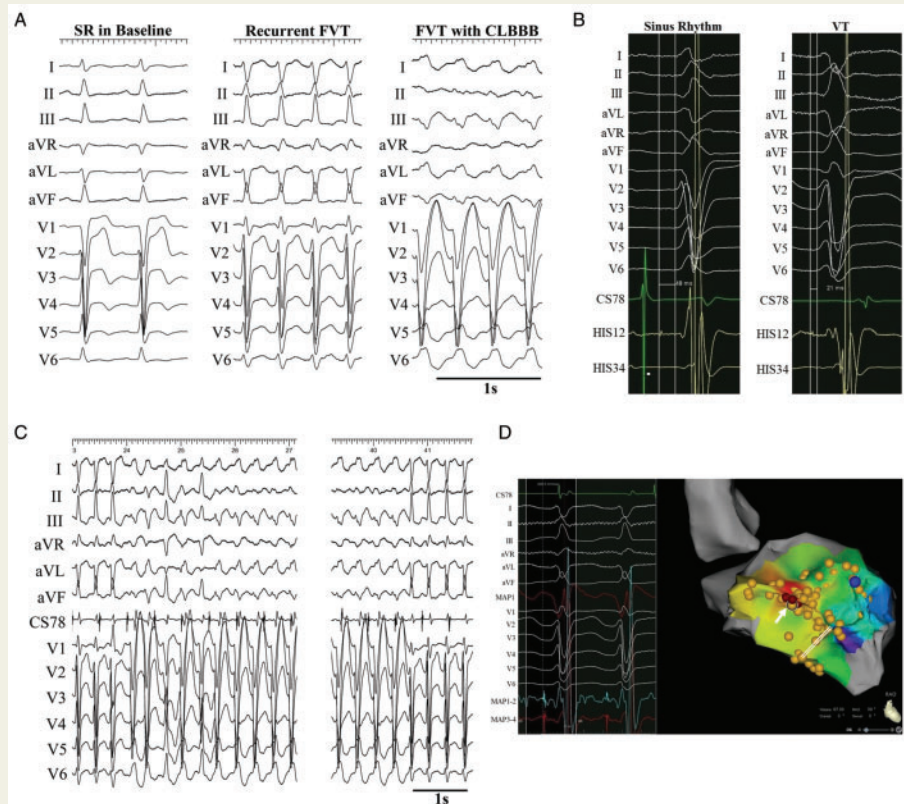


Figure 1 (A) QRS morphology during sinus rhythm, fascicular ventricular tachycardia (FVT), and FVT with complete left bundle branch block (CLBBB). (B) HV interval during sinus rhythm and FVT. (C) CLBBB occurred during FVT due to left anterior fascicle mechanical injury and maintained for 16 s without terminating or prolonging the FVT. (D) The site with the earliest Purkinje potential recorded near the proximal area of left posterior fascicle was the successful ablation target (white arrow). Blue dot was the position of the ablation catheter when mechanical bump occurred. Double solid line indicated the possible previous ablation lesions according to double or split Purkinje potential mapped.